SEUP SOCIEDAD ESPAÑOLA DE URGENCIAS DE PEDIATRÍA

EMERGENCIASPediátricas
Vol. 5. No. 3

Emergencias Pediátricas. 2026; 5(3): –

CLINICAL CASE

Superior mesenteric artery syndrome in a pediatric patient: failure of conservative treatment and laparoscopic resolution. A case report

Nicolás Falcón Naser[1*], **José Campos Varas**[1], **Josefina Saez Binelli**[2], **Luis Ziehe Moreira**[3]

[1] *Pediatric Surgery, Hospital de Niños Dr. Roberto del Río, Santiago, Chile* [2] *Pediatric Surgery, School of Medicine, Faculty of Medicine, Pontificia Universidad Católica de Chile. Santiago, Chile.* [3] *Department of Radiology of the Hospital Clínico de la Pontificia Universidad Católica de Chile, Santiago, Chile.*

Received April 28, 2026
Accepted June 20, 2026
Published November 20, 2026

Keywords:
Duodenal obstruction
Superior mesenteric artery syndrome
Wilkie syndrome
Pediatrics
Duodenojejunostomy
Laparoscopy

Palabras clave:
Obstrucción duodenal
Síndrome de la arteria mesentérica superior
Síndrome de Wilkie
Pediatría
Duodenoyeyunostomía
Laparoscopía

Abstract

Introduction: Superior mesenteric artery syndrome (SMAS) is an uncommon cause of duodenal obstruction in children, and its diagnosis is often delayed because of nonspecific symptoms. Initial management is conservative, with surgery reserved for refractory cases. Case Report: An 11-year-old previously healthy girl presented with epigastric pain and postprandial vomiting. Computed tomography showed an aortomesenteric angle of 6° and a distance of 4 mm, confirming SMAS. Conservative treatment with gastric decompression and enteral nutrition via a nasojejunal tube was initiated. However, the patient experienced early symptom recurrence, and contrast imaging confirmed persistent obstruction. Laparoscopic duodenojejunostomy was therefore performed, with a favorable postoperative course and complete symptom resolution. Discussion: This case highlights the need to consider SMAS in adolescents presenting with upper intestinal obstruction in the absence of classic predisposing factors, and demonstrates that laparoscopic duodenojejunostomy is a safe and effective alternative when conservative management fails.

SÍNDROME DE LA ARTERIA MESENTÉRICA SUPERIOR EN PEDIATRÍA: FRACASO DEL TRATAMIENTO CONSERVADOR Y RESOLUCIÓN LAPAROSCÓPICA. REPORTE DE UN CASO

Resumen

Introducción: El síndrome de la arteria mesentérica superior (SAMS) es una causa infrecuente de obstrucción duodenal en pediatría, cuyo diagnóstico suele retrasarse por la inespecificidad de los síntomas. El manejo inicial es conservador, reservando la cirugía para los casos refractarios. Caso Clínico: Se presenta una niña de 11 años previamente sana, con dolor epigástrico y vómitos postprandiales. La tomografía computarizada mostró un ángulo aorto-mesentérico de 6° y una distancia de 4 mm, confirmando SAMS. Se indicó tratamiento conservador con

© 2026 The authors. This article is distributed under the terms of the **Creative Commons Attribution 4.0 International License (CC BY 4.0)**. Published by index on behalf of the Sociedad Española de Urgencias de Pediatría (SEUP) and the Sociedad Latinoamericana de Emergencia Pediátrica (SLEPE).

descompresión gástrica y nutrición enteral mediante sonda nasoyeyunal. Sin embargo, la paciente presentó recurrencia precoz de los síntomas y persistencia de la obstrucción demostrada mediante estudio contrastado, por lo que se realizó una duodenoyeyunostomía laparoscópica, con evolución postoperatoria favorable y resolución completa de los síntomas. Comentarios: Este caso destaca la necesidad de considerar el SAMS ante cuadros de obstrucción alta en adolescentes sin factores predisponentes clásicos, y demuestra que la duodenoyeyunostomía laparoscópica es una alternativa segura y eficaz cuando fracasa el manejo conservador.

*Corresponding author:
Nicolás Falcón Naser
Email:
nicolas.falcon@gmail.com

INTRODUCTION

Superior mesenteric artery syndrome (SMAS) is an uncommon cause of upper intestinal obstruction, with an estimated prevalence of 0.013% to 0.3%[1]. It is more common in women, with a ratio of 3:2[2].

In the pediatric population, SMAS is an uncommon cause of intestinal obstruction[2]. The literature on this age group is limited, contributing to a low index of diagnostic suspicion and, consequently, delays in identification. Its presentation may mimic other, more prevalent gastrointestinal conditions; therefore, it is essential to consider it in the differential diagnosis, especially in adolescents with compatible symptoms.

Classically, SMA syndrome has been associated with rapid weight loss or spinal surgery; however, cases have also been described in the absence of these predisposing factors[2,3].

Clinically, the most common symptoms include postprandial abdominal pain (predominantly epigastric), nausea, vomiting, anorexia, and early satiety. This presentation is usually chronic, although it may become acute with a high intestinal obstruction[4].

Initial management is conservative and aims to relieve the obstruction, restore retroperitoneal fat padding, and improve the patient's nutritional status. Surgical intervention is reserved for cases in which medical treatment fails[4].

The objective of this article is to present the clinical case of a previously healthy adolescent who developed a presentation consistent with upper intestinal obstruction and was diagnosed with SMAS. The aim is to highlight its relevance in the differential diagnosis of intestinal obstruction, the challenges inherent in identifying it, and the stepwise therapeutic approach.

This study was conducted in accordance with the CARE (CAse REports) guidelines[5].

CLINICAL CASE

An 11-year-old girl with no significant medical history presented to the emergency department with epigastric abdominal pain and a one-day history of vomiting. Physical examination revealed no significant findings. Abdominal ultrasound was reported as normal, and symptomatic outpatient treatment was prescribed. Five days later, she returned with persistent symptoms, now accompanied by early satiety. She had no medical or surgical history, and her body habitus was mesomorphic (height: 147 cm; weight: 36 kg; BMI: 16.6 [29th percentile]). On admission, she had signs of mild dehydration, normal vital signs, and epigastric tenderness on palpation. A plain abdominal radiograph showed gastric dilatation with air-fluid levels in the gastric fundus and first portion of the duodenum [Figure 1a]. Repeat abdominal ultrasound showed marked gastric dilatation with abundant retained contents, associated with dilatation of the first and second portions of the duodenum. In view of these findings, contrast-enhanced computed tomography of the abdomen and pelvis was performed, revealing an abrupt change in caliber at the third portion of the duodenum as it passed between the aorta and the superior mesenteric artery, with collapse of the distal small bowel loops. The aortomesenteric angle was 6° and the aortomesenteric distance was 4 mm [Figures 1b, c and d].

The patient was hospitalized with a diagnosis of intestinal obstruction secondary to SMAS. A tube was placed for gastric decompression, and she was kept strictly nil by mouth (oral feeding was suspended) and given intravenous fluids. Subsequently, on the second attempt and under general anesthesia, a nasojejunal tube was placed beyond the site of obstruction with fluoroscopic and endoscopic guidance. Continuous enteral feeding was initiated, and she was discharged in good condition to continue outpatient management.

Two days after discharge, at follow-up in the surgical outpatient clinic, the patient was asymptomatic, tolerating oral fluids and receiving the remainder of her nutrition via a nasojejunal tube. A contrast study of the esophagus, stomach, and duodenum was requested to confirm resolution of the intestinal obstruction.

Six days later, she presented to the emergency department with bilious vomiting and epigastric abdominal pain that was relieved by lying in the left lateral decubitus position. On physical examination, the abdomen was not distended but was tender in the epigastrium. The nasojejunal tube remained in situ, and its position was confirmed by radiography. Given the recurrence of symptoms, she was admitted for contrast imaging and to determine whether surgical intervention would be necessary.

The following day, a barium contrast study demonstrated persistent dilation of the proximal duodenum, with an abrupt change in caliber at the level of the third portion of the duodenum and minimal passage of contrast distally despite the presence of an enteral tube [Figure 2a].

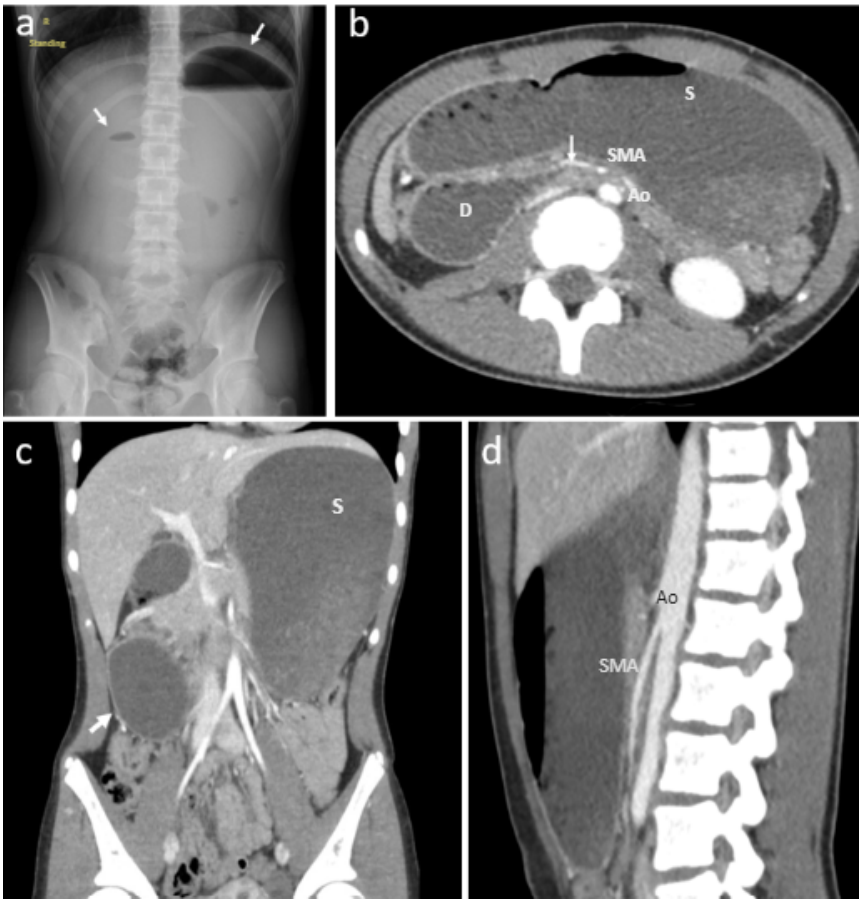

FIGURE 1. a) Standing anteroposterior plain abdominal radiograph showing dilatation of the gastric chamber and air-fluid levels in the gastric fundus and the first portion of the duodenum (arrows). b, c, d) Computed tomography (CT) of the abdomen and pelvis in the portal venous phase. b) The axial image shows air-fluid dilatation of the gastric chamber (S) and the second portion of the duodenum (D), with a change in caliber in the third portion (white arrow) at the crossing between the superior mesenteric artery (SMA) and the abdominal aorta (Ao). c) Coronal reconstruction showing marked fluid-filled distension of the gastric chamber (S) and of the first and second portions of the duodenum (arrow). d) Sagittal reconstruction. Aortomesenteric angle of 6° and aortomesenteric distance of 4 mm.

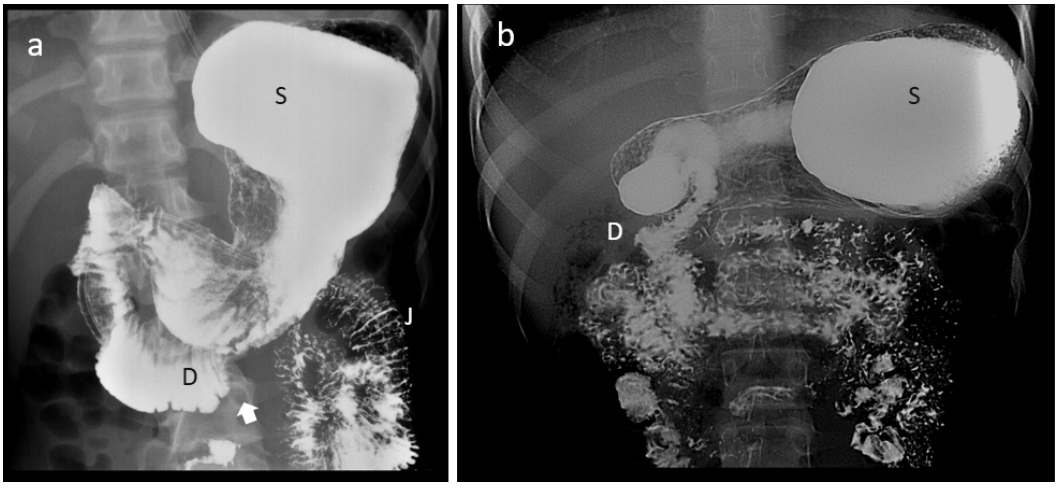

FIGURE 2. a) AP abdominal radiograph with oral barium contrast showing moderate distension of the gastric chamber (S) and of the duodenum (D), with a persistent abrupt change in caliber in the third portion (arrow). An enteral tube is seen with its distal tip in the proximal jejunum (J). b) Postoperative follow-up AP abdominal radiograph with oral barium contrast showing resolution of the duodenal dilatation (D) and of the previously visualized change in caliber.

Given the persistence of the duodenal obstruction documented on the contrast study, the early recurrence of symptoms despite distal enteral nutrition via a nasojejunal tube, and the absence of a reversible predisposing factor that could be corrected with prolonged nutritional

support, surgical treatment was indicated without prolonging conservative management.

Under general anesthesia and in the supine position, a laparoscopic approach was performed. A 10-mm umbilical port was placed using the Hasson technique for the 10-mm, 30-degree laparoscope, along with two 5-mm ports in both flanks and a 12-mm port in the left upper quadrant. The transverse colon was displaced cephalad, and the dilated and elongated second and third portions of the duodenum were identified. The second and third portions of the duodenum were dissected via an inframesocolic approach from the adjacent structures to mobilize them and free them from the retroperitoneum. A segment of proximal jejunum was brought up to the mobilized duodenum, and two proximal and distal anchoring sutures were placed between the duodenum and jejunum along the antimesenteric border using 3/0 Vicryl [Figure 3a]. An enterotomy was made in both segments [Figure 3b], and an intracorporeal side-to-side duodenojejunostomy was performed using a 60-mm Tri-Staple mechanical stapler (3.0/3.5/4.0 mm) [Figure 3c]. The enterotomy was then closed with a running 3/0 Vicryl suture and reinforced with interrupted sutures of the same material [Figure 3d]. The port sites were closed in two layers: 2/0 Vicryl in the deep layer and 4/0 Monocryl in the skin. The patient left the operating room without a nasojejunal tube.

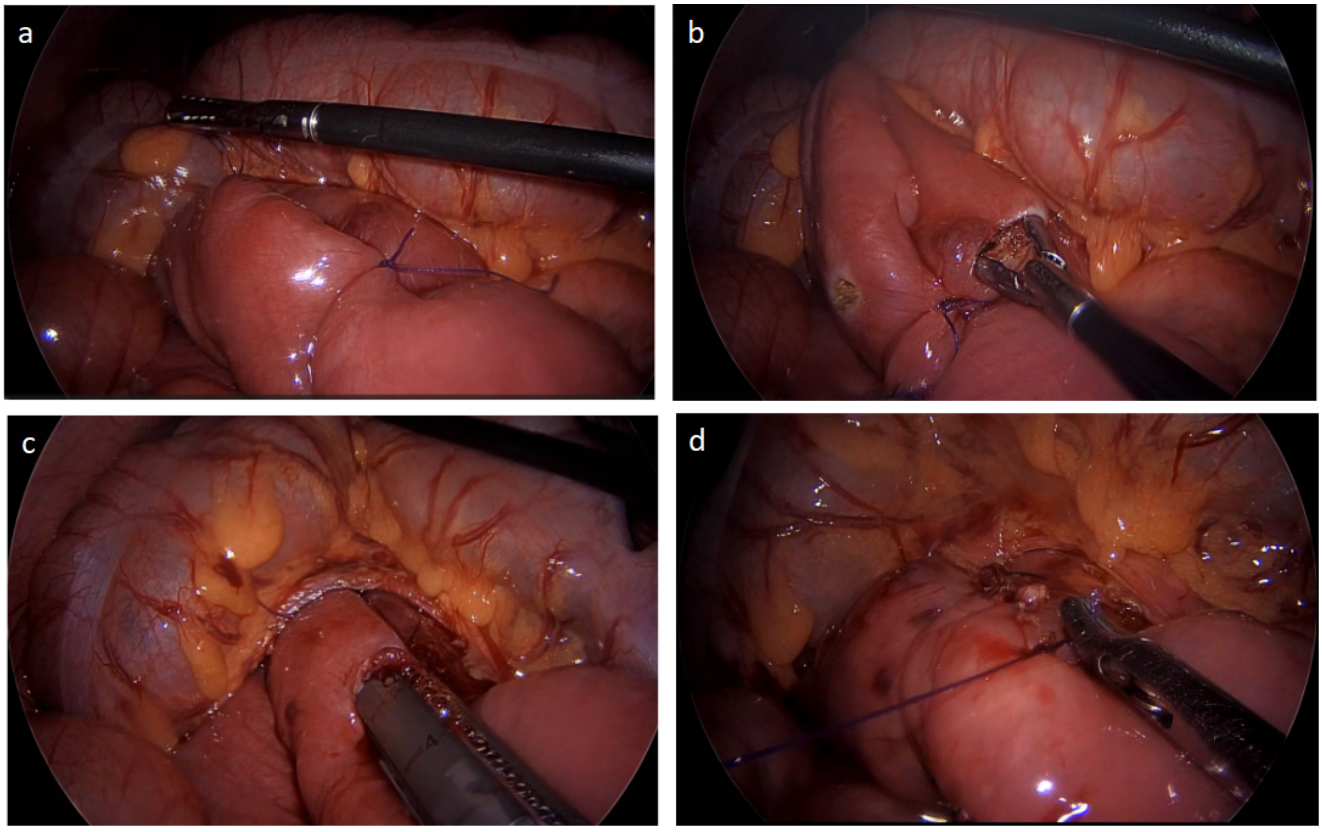

FIGURE 3. Sequence of laparoscopic duodenojejunostomy. a) Duodenal and jejunal segments approximated and fixed with proximal and distal stitches. b) Enterotomy in both segments. c) Duodenojejunal anastomosis with a mechanical stapler. d) Closure of the enterotomy with a running suture.

Postoperatively, her course was favorable. She started oral feeding at 24 hours and tolerated it well. She was discharged on postoperative day 3 without complications. At the two-week follow-up, she was asymptomatic and tolerating oral intake well, with no dietary restrictions. At the three-month follow-up, she remained symptom-free, and a repeat contrast study showed a nondilated duodenal loop with adequate passage of contrast into the jejunum [Figure 2b]. She remains asymptomatic 7 months postoperatively.

DISCUSSION

Superior mesenteric artery syndrome (SMAS), also known as Wilkie syndrome or duodenal compression syndrome, is an uncommon cause of upper intestinal obstruction resulting from entrapment of the third portion of the duodenum between the superior mesenteric artery (SMA) and the aorta[6]. This condition was first described in 1861 by Rokitansky and later clinically characterized by Wilkie in 1921[6]. Its prevalence is low, with estimates ranging from 0.01% to 0.3%[6].

Despite its rarity, SMAS should be considered in the differential diagnosis of patients with symptoms of upper

intestinal obstruction, especially young women between 10 and 39 years of age[6,7]. This profile is consistent with our patient, who presented with recurrent postprandial vomiting and epigastric pain in the absence of classic predisposing factors such as significant weight loss, eating disorders, spinal surgery, or psychiatric illness. In pediatric patients, this idiopathic presentation is not uncommon, as reported by Okamoto et al., who found a significant proportion of cases without evident triggers[8].

The pathophysiology of SMAS involves a decrease in the aortomesenteric angle (normally between 28° and 65°) and the SMA-to-aorta distance (normally 10 to 34 mm), leading to extrinsic compression of the duodenum[9,10]. In our patient, the angle was 6° and the distance was 4 mm, values within the proposed diagnostic ranges (<22° and <8 mm, respectively)[10]. Computed tomography with multiplanar reconstruction has been shown to be the method of choice for confirming these findings[9], while also allowing other obstructive causes to be ruled out.

Although contrast studies and plain radiographs can provide preliminary information, they cannot confirm the diagnosis[10]. Imaging may show gastric and proximal duodenal dilation, as well as distal duodenal collapse as it passes beneath the SMA[9]. In some cases, as Ünal et al. note, ultrasonography may be useful for measuring the aortomesenteric angle, although its utility depends on the operator's experience and the patient's anatomical conditions[10].

One of the main challenges in managing SMAS is the low level of clinical suspicion resulting from the nonspecific nature of its symptoms. In this case, although the interval from symptom onset to diagnosis was relatively short, the patient required multiple consultations and investigations before the definitive diagnosis was established, a situation frequently described in the pediatric literature. This delay is consistent with the findings reported by Shin and Kim, who observed a median of 68 days from symptom onset to diagnosis in a pediatric series[11]. Such delays may lead to secondary malnutrition, worsening symptoms, and multiple unnecessary investigations.

Initial treatment of SMA syndrome is conservative and aims to restore the retroperitoneal fat pad that separates the superior mesenteric artery from the aorta[10]. This is achieved through postpyloric enteral feeding, positioning (left lateral decubitus or knee-chest position), and parenteral nutrition when necessary. In our patient, placement of a nasojejunal tube proved technically challenging, a difficulty reported relatively frequently in the pediatric population. In addition, the absence of a reversible precipitating factor likely reduced the probability of success with conservative treatment, a situation previously associated with a poor response to medical management[11].

In this context, although some authors recommend continuing conservative treatment for four to six weeks before considering surgery, this period should be individualized according to each patient's clinical course. Persistent duodenal obstruction demonstrated on imaging studies, recurrent symptoms, and inability to advance oral feeding are reasonable criteria for considering early surgical intervention, particularly when no reversible factor can be identified, thereby avoiding prolonged hospitalization and progressive nutritional deterioration. Our patient met these criteria, and surgical treatment was therefore indicated after failure of the initial conservative management was demonstrated.

Once conservative treatment has been established as unsuccessful, the various surgical alternatives should be considered. Among them, the Strong procedure (division of the ligament of Treitz) offers the advantage of avoiding an intestinal anastomosis; however, failure rates of up to 25% have been reported, attributed to persistent traction exerted by the inferior pancreaticoduodenal arcade[6]. For this reason, duodenojejunostomy is currently considered the procedure of choice in refractory cases, with high success rates and a low incidence of complications[6,7].

Consistent with this evidence, laparoscopic duodenojejunostomy was chosen for our patient, a technique that combines the procedure's efficacy with the inherent advantages of minimally invasive surgery. Ehlers et al. reported complete symptom resolution and weight gain in patients who underwent laparoscopic duodenojejunostomy[7]. Similarly, Pottorf et al. observed a 92% success rate, with no major complications and an average hospital stay of 4.2 days[6]. In our case, the patient had a favorable postoperative course, beginning oral intake 24 hours after surgery and being discharged on postoperative day three, supporting the benefits of the laparoscopic approach in terms of early recovery, less postoperative pain, shorter hospital stay, and reduced risk of abdominal wall complications[6].

Despite the favorable outcome, this report has the limitations inherent to a single case report, which restrict the generalizability of its findings. Although the diagnosis was confirmed by computed tomography and supplemented by a contrast study, the main challenge was the low initial clinical suspicion, which led to multiple evaluations before the definitive diagnosis was established. Nevertheless, this case illustrates an idiopathic presentation of SMAS in a pediatric patient without classic predisposing factors and demonstrates the feasibility and efficacy of laparoscopic duodenojejunostomy following failure of conservative treatment.

In conclusion, this case underscores the importance of including SMAS in the differential diagnosis of abdominal pain and recurrent vomiting, even in eutrophic patients without predisposing factors. CT with multiplanar reconstruction is essential for diagnosis, and a laparoscopic approach to duodenojejunostomy represents a safe, effective, and reproducible option in pediatric patients. Early recognition of this condition can prevent prolonged hospitalizations, unnecessary procedures, and significant nutritional deterioration. This case also highlights the importance of individualizing the duration of conservative treatment and considering early surgical intervention

when there is objective evidence of failure of medical management.

STATEMENTS

Acknowledgments:

To Dr. Lukas Karachon Essedin, radiologist at Hospital Clínico UC CHRISTUS Santiago (Chile), for his valuable contribution to the patient's diagnostic process by interpreting the CT scan and promptly identifying superior mesenteric artery syndrome as the cause of the intestinal obstruction.

Funding

No funding was received for the research, authorship, and/or publication of this article.

Conflict of interest

I declare that there is no commercial or financial conflict of interest in this research.

Author Contributions

Nicolás Falcón Naser: Conceptualization, Formal analysis, Writing, reviewing, and editing, Data collection, Methodology, Investigation, Visualization, Writing - initial draft; Luis Ziehe Moreira: Visualization, Methodology, Supervision, Writing, reviewing, and editing; Jose Campos Varas: Conceptualization, Writing, reviewing, and editing, Formal analysis, Visualization, Investigation, Methodology, Supervision; Josefina Saez Binelli: Supervision, Writing, reviewing, and editing, Formal analysis, Project management

Ethical-Scientific Statement:

This study was approved by the Research Ethics Committee of the Northern Metropolitan Health Service.

Use of AI

I declare that no artificial intelligence tools (such as ChatGPT, Copilot, Gemini, or others) were used in the drafting, analysis, or review of this article.

Data availability

The data supporting the findings of this study are available from the corresponding author upon request.

REFERENCES

1. Mandarry MT, Zhao L, Zhang C, Wei ZQ. A comprehensive review of superior mesenteric artery syndrome. European Surgery. 2010;42(5):229–236. Available at: https://doi.org/10.1007/s10353-010-0561-y.
2. Biank V, Werlin S. Superior Mesenteric Artery Syndrome in Children: A 20-Year Experience. Journal of Pediatric Gastroenterology and Nutrition. 2006;42(5):522–525. Available at: https://doi.org/10.1097/01.mpg.0000221888.36501.f2.
3. Mauney CA, Florissi I, Etchill EW, Garcia AV. Laparoscopic duodenojejunostomy for the treatment of pediatric superior mesenteric artery syndrome: A case series. Journal of Pediatric Surgery Open. 2023;4:100065. Available at: https://doi.org/10.1016/j.yjpso.2023.100065.
4. Welsch T, Büchler MW, Kienle P. Recalling Superior Mesenteric Artery Syndrome. Digestive Surgery. 2007;24(3):149–156. Available at: https://doi.org/10.1159/000102097.
5. Gagnier JJ, Kienle G, Altman DG, Moher D, Sox H, Riley D. The CARE Guidelines: Consensus-Based Clinical Case Reporting Guideline Development. Headache: The Journal of Head and Face Pain. 2013;53(10):1541–1547. Available at: https://doi.org/10.1111/head.12246.
6. Pottorf BJ, Husain FA, Hollis HW, Lin E. Laparoscopic Management of Duodenal Obstruction Resulting From Superior Mesenteric Artery Syndrome. JAMA Surgery. 2014;149(12):1319. Available at: https://doi.org/10.1001/jamasurg.2014.1409.
7. Ehlers T-O, Tsamalaidze L, Pereira L, Stauffer J. Laparoscopic Duodenojejunostomy for the SMA Syndrome. Zentralblatt für Chirurgie - Zeitschrift für Allgemeine, Viszeral-, Thorax- und Gefäßchirurgie. 2018;143(05):461–463. Available at: https://doi.org/10.1055/a-0668-1991.
8. Okamoto T, Sato T, Sasaki Y. Superior mesenteric artery syndrome in a healthy active adolescent. BMJ Case Reports. 2019;12(8):e228758. Available at: https://doi.org/10.1136/bcr-2018-228758.
9. Raman SP, Neyman EG, Horton KM, Eckhauser FE, Fishman EK. Superior mesenteric artery syndrome: spectrum of CT findings with multiplanar reconstructions and 3-D imaging. Abdominal Imaging. 2012;37(6):1079–1088. Available at: https://doi.org/10.1007/s00261-012-9852-z.
10. Unal B, Aktaş A, Kemal G, Bilgili Y, Güliter S, Daphan C, et al. Superior mesenteric artery syndrome: CT and ultrasonography findings. Diagn Interv Radiol. 2005;11(2):90–95.
11. Shin MS, Kim JY. Optimal Duration of Medical Treatment in Superior Mesenteric Artery Syndrome in Children. Journal of Korean Medical Science. 2013;28(8):1220. Available at: https://doi.org/10.3346/jkms.2013.28.8.1220.